

**PennHIP Report**

Referring Veterinarian: Dr Jason Rowan	Clinic Name: Pandosy Village Veterinary Hospital
Email: jason@pandosyvet.com	Clinic Address: 2720 Richter Street Kelowna, BC V1Y 2R5
	Phone: (778) 478-7088
	Fax: (778) 653-0598

**Patient Information**

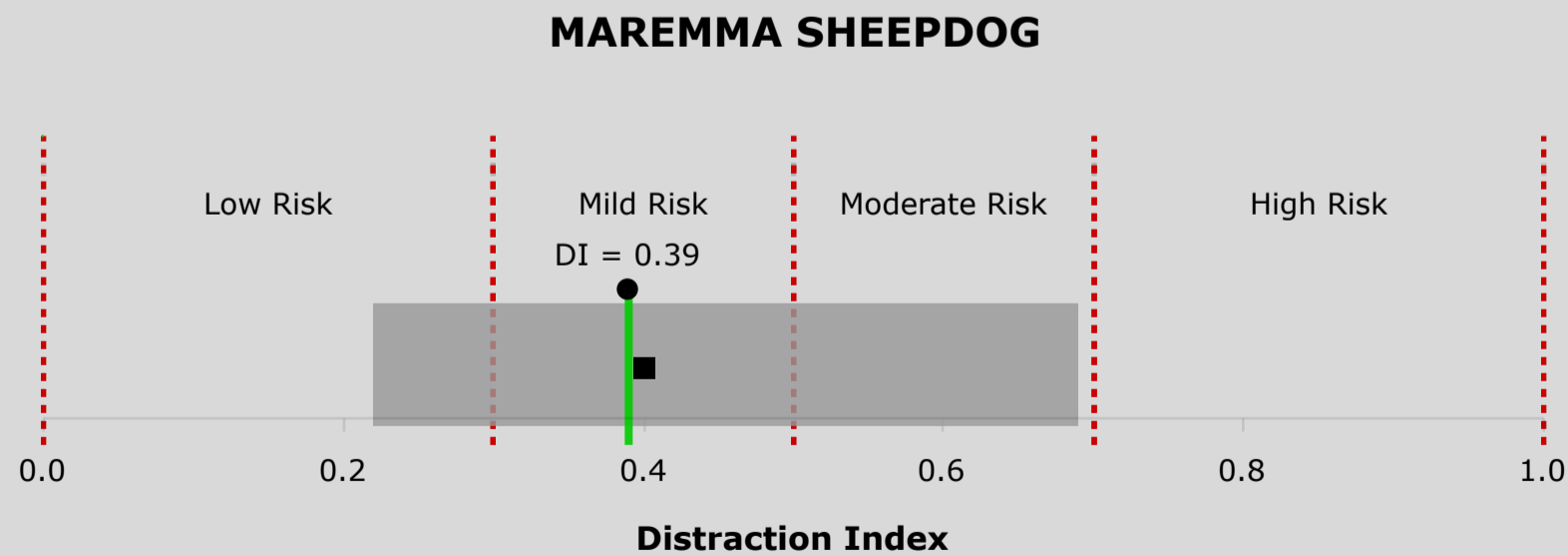
Client: Ribaux, Allison	Tattoo Num:
Patient Name: Chive	Patient ID: 8242
Reg. Name:	Registration Num:
PennHIP Num: 185507	Microchip Num:
Species: Canine	Breed: MAREMMA SHEEPDOG
Date of Birth: 10 May 2022	Age: 9 months
Sex: Male	Weight: 97 lbs/44 kgs
Date of Study: 23 Feb 2023	Date Submitted: 23 Feb 2023
Date of Report: 26 Feb 2023	

**Findings**

Distraction Index (DI): Right DI = 0.39, Left DI = 0.39.
Osteoarthritis (OA): <b>No radiographic evidence of OA for either hip.</b>
Cavitation/Other Findings: No cavitation present.

**Interpretation**

Distraction Index (DI): The laxity ranking is based on the hip with the greater laxity (larger DI). In this case the DI used is 0.39.  
 OA Risk Category: The DI is between 0.31 and 0.49. This patient is at mild risk for hip OA.  
 Distraction Index Chart:



**BREED STATISTICS:** This interpretation is based on a cross-section of 234 canine patients of the MAREMMA SHEEPDOG breed in the AIS PennHIP database. The gray strip represents the central 90% range of DIs (0.22 - 0.69) for the breed. The breed average DI is 0.40 (solid square). The patient DI is the solid circle (0.39).

**SUMMARY:** The degree of laxity (DI = 0.39) falls within the central 90% range of DIs for the breed. This amount of hip laxity places the hip at a mild risk to develop hip OA. **No radiographic evidence of OA for either hip.**